



ELSEVIER

Journal of  
Pediatric  
urology

REVIEW ARTICLE

# Balanitis xerotica obliterans in children and adolescents: A literature review and clinical series



Soledad Celis<sup>a,b</sup>, Francisco Reed<sup>a,e</sup>, Feilim Murphy<sup>c</sup>,  
Stephen Adams<sup>c</sup>, John Gillick<sup>f</sup>, Abdelhafeez H. Abdelhafeez<sup>f</sup>,  
Pedro-Jose Lopez<sup>a,b,d,\*</sup>

<sup>a</sup> Pediatric Urology Service, Dr. Exequiel González Cortés Hospital, Santiago, Chile

<sup>b</sup> School of Medicine, Department of Pediatrics and Pediatric Surgery, University of Chile, Santiago, Chile

<sup>c</sup> St Georges Hospital, London, UK

<sup>d</sup> Clínica Alemana, Santiago, Chile

<sup>e</sup> Clínica Santa María, Santiago, Chile

<sup>f</sup> Temple Street University Hospital, Dublin, Ireland

Received 6 June 2013; accepted 27 September 2013

Available online 14 November 2013

## KEYWORDS

Balanitis xerotica obliterans;  
Lichen sclerosus et atrophicus;  
Pediatric adolescents review treatment;  
Phimosis

**Abstract** *Objective:* Balanitis xerotica obliterans (BXO) is a chronic inflammatory disease that is considered as male genital variant lichen sclerosis. The incidence varies greatly in different series; diagnosis is mostly clinical but histopathological confirmation is mandatory. Various treatments are described, but there is no consensus that one is the best.

*Materials and methods:* A literature review was made of BXO and lichen sclerosis in boys under 18 years of age, between 1995 and 2013, analyzing demographic dates, treatments and outcomes. In addition to that, we reviewed BXO cases treated in our centers in the last 10 years.

*Results:* After literature review, only 13 articles matched the inclusion criteria. Analyzing those selected, the global incidence of BXO is nearly 35% among circumcised children. Described symptoms are diverse and the low index of clinical suspicion is highlighted. The main treatment is circumcision, with use of topical and intralesional steroids and immunosuppressive agents.

\* Corresponding author. Pediatric Urology Service, Hospital Dr. Exequiel González Cortés & Clínica Alemana, Barros Luco 3301, San Miguel, Santiago, Chile. Tel.: +56 2 4605408; fax: +56 2 5546710.

E-mail addresses: [pejotalopez@yahoo.com](mailto:pejotalopez@yahoo.com), [pedrojose@cirupedia.cl](mailto:pedrojose@cirupedia.cl) (P.-J. Lopez).

**Conclusion:** BXO is a condition more common than we believe and we must be vigilant to find greater number of diagnoses to avoid future complications. The main treatment for BXO is circumcision, but as topical or intralesional treatments are now available with potentially good outcomes, they may be considered as coadjuvants.

© 2013 Published by Elsevier Ltd on behalf of Journal of Pediatric Urology Company.

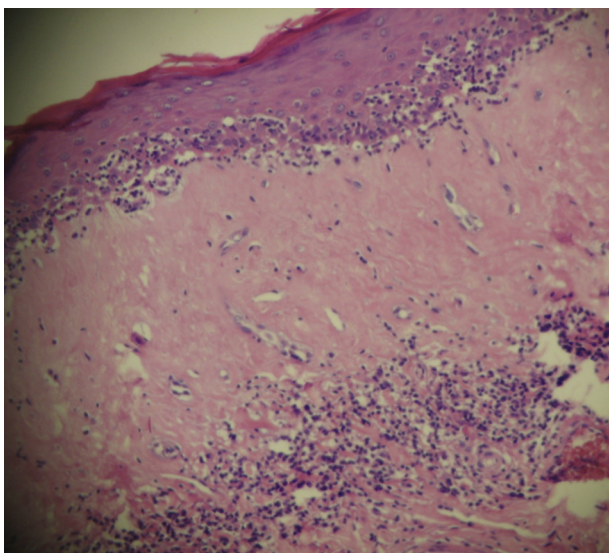
## Introduction

Balanitis xerotica obliterans (BXO) is a chronic inflammatory disease of unclear etiology, which can affect the foreskin, frenulum, glans, meatus and urethra. It was described in 1928, by Stuhmer [1], and is considered as the male genital variant of Lichen Sclerosus. The name was derived from the three components of the disease, which are *balanitis* – chronic inflammation of the glans penis – *xerotic* – abnormally dry appearance of the lesion – and *obliterans* – association of occasional endarteritis [2].

The first case was reported in 1962 by Caterall and Oates in a 7-year-old child [3]. As then, the true incidence is not clear. In children with phimosis it ranges from 9% to more than 50% in different series [4–7]. There have been cases reported in neonates, with an increased incidence in the last couple of decades. The prevalence described in pre-puberty is about 0.01–0.07% [8].

The diagnosis is mostly clinical initially, with secondary phimosis, white xerotic appearance of glans and foreskin, dysuria and even urinary retention. The diagnosis is confirmed via histology revealing hyperkeratosis and atrophy of the basal layer of the epidermis with loss of elastic fibers and collagen alterations with inflammatory infiltration (Fig. 1) [5,10].

The classic treatment is surgery, with a wide spectrum of interventions, from circumcision to more complex reconstructive urethral surgeries; however, in the last few



**Figure 1** Histological diagnosis revealing hyperkeratosis and atrophy of the basal layer of the epidermis with loss of elastic fibers and collagen alterations with inflammatory infiltration.

years, several publications have supported the use of coadjuvant treatments pre or post surgery and/or associated conservative treatments.

The aim of this paper is to review the literature, presenting the current understanding of BXO, incidence and the available treatments for the pediatric group, as well as report the authors' combined recent experience.

## Materials and methods

A literature review was undertaken using Pubmed, Medline and Cochrane looking for reports in which balanitis xerotica obliterans and lichen sclerosus appear as keywords. Two filters were used; only male children under 18 years old and papers from year 1995 onward were included. Additionally, directed searches from the main publications among urology and pediatric surgery annals were done. Publications including patients over 18 years old, women, other locations for lichen sclerosus and no clinical trials were excluded.

In addition, a complete review of BXO cases treated in three pediatric surgical centers with different patient demographics between 2002 and 2012 was carried out, analyzing treatment and results.

## Results

In the first stage of the review, a total of 37 articles, which met the inclusion criteria, were found; 18 were excluded because of the exclusion criteria previously defined. Three articles were excluded because they were only case reports; one because the same research group had an article with more data included published afterwards and two because they did not provide information to the topics searched in this review.

A final analysis for 13 articles was made, with the emphasis on BXO incidence, diagnosis and coadjuvant treatments [5–7,10–18].

## Incidence

The incidence of BXO varies greatly in the reported literature, from 5% to 52% [5–10], with an increase in recent publications. The true incidence of BXO calculated in this review is 35% (Table 1). This was done reviewing the main articles that based their analysis of every prepuce circumcised obtained with histopathology. This incidence was calculated by selecting all articles in which foreskin samples, regardless of the cause of circumcision, were sent to histopathological analysis. These articles do not include newborn foreskin [5–7,9–12].

**Table 1** Incidence BXO.

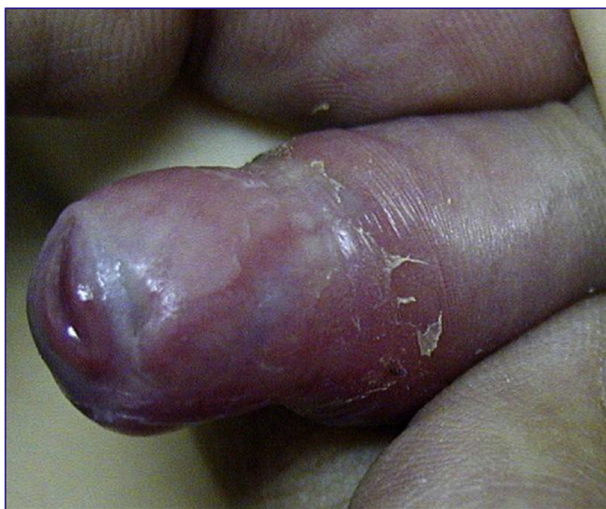	<i>n</i>	Incidence BXO	Mean age	
Kiss (2005)	1178	(471) 40%	6.8	7 (1.5%) Meatal stenosis
Bochove-Overgaauw (2009)	135	(37) 27%	6.5	6 (4%) Meatal stenosis
Jayakumar (2012)	346	(182) 52.6%	9	
Yardley (2007)	148	(51) 34.5%	6.2	
Pilatz (2013)	150	(8) 5%	6	
Ebert (2008)	222	(20) 9%	9.7	
Mattioli (2002)	115	(47) 40%	7	
	2294	(816) 35%	7.31	

It is worth mentioning that the highest incidence is seen in publications from urology services [5], which could represent selection bias.

It is worth highlighting that the study population in the report by Jayakumar et al., presented an incidence of 19.3% of BXO in samples obtained in children under 5 years old [5]. This fact may alert us to the possibility of the presence of this pathology at early ages, contradicting the current teaching.

### Clinical presentation

Classically, signs and symptoms observed in BXO in uncircumcised children are progressive phimosis, typically appearing as a whitish ring with discoloration of the glans,



**Figure 2** Classically appearance observed in BXO in uncircumcised children; phimosis and a whitish ring with discoloration of the glans.

secondary phimosis, dysuria and ballooning of the foreskin with voiding (Fig. 2) [6,12,14].

Among the most frequent symptoms found were the non-retractability of the prepuce, ballooning and dysuria. It is important to mention that hypospadias associated with BXO were reported in two series, with a 15% and 20% of the foreskins studied [10,12].

Correlating BXO histopathological diagnosis and clinical suspicion, studies indicates a diagnosis accuracy of 53% (0–88%) (Table 2) [5,7,9–14,16,18].

In summary, the clinical suspicion of BXO is unreliable, therefore clinical diagnosis is suspect. To detect a larger number of cases, all foreskin samples should be sent to pathology for histopathological analysis or at least those with suspicious foreskin and/or secondary phimosis from older children.

### Etiology – physiopathology

BXO is a lymphocyte-mediated chronic inflammatory disease of the foreskin, but the etiology and development is unknown. There is increasing evidence for an underlying autoimmune mechanism [2,19]; however, an infectious cause has often been postulated, viral, acid fast bacilli and spirochetes, but testing has not been conclusive [2,19,20]. Genetic predisposition, chronic irritation through urine exposure and hormonal influences are other possible theories [2].

Currently, the evidence indicates an autoimmune derived pathogenesis for BXO lesions, histologically characterized by an abundance of infiltrating, auto reactive cytotoxic T lymphocytes, impaired metabolism of extracellular matrix and the presence of autoantibodies to extracellular matrix protein in serum [9].

There are relatively few studies regarding the pathophysiology of BXO in children; however, the Pilatz study, based on assessed molecular features of BXO, revealed an up-regulation of 11 genes in boys with BXO, principally pro-inflammatory and proteins pivotal for tissue remodeling [9]. This is similar to that found in lichen sclerosis in adults, as the same pathways seem to be involved in the genesis of BXO in boys [21,22].

### Treatment

The recommended treatment for BXO in the uncircumcised patient is circumcision. This is the first treatment line in 10 of the 13 articles reviewed and in many cases is curative by itself, without other interventions [5–7,9–15,18]. It is worth mentioning, however, that in a series of 10 patients who underwent partial circumcision (foreskin conservative), five (50%) had a recurrence [13], but none had adjuvant treatment.

In analyzing additional or alternative treatments to circumcision, the use of corticosteroids has been described before surgery [15,16], at the time of surgery [16,17] and after surgery [7], and the use of topic immunosuppressant such as tacrolimus has also been described [12].

Two reports used corticosteroids as first line treatment in suspected BXO [15,16]. In both studies, the diagnosis was made clinical without histological confirmation. In the

**Table 2** Clinical presentation.

	Clinical suspicion	Phimosis	Hypospadias	Meatal stenosis	Dysuria	Ballooning	Recurrent balanitis
Ebert	75%	75%	20%	5%			
Mattioli	0%	60%/30% <sup>a</sup>	15%				1%
Gargollo	88%			37%	48.8%	24.4%	22%
Jayakumar	50%				33% <sup>b</sup>	33% <sup>b</sup>	50% <sup>b</sup>
Bochove-Overgaauw	51%						
Becker	65%	80% (acquired)					
Vincent	100% <sup>c</sup>	100% <sup>c</sup>			32%	53%	
Mohammed	5%	70%					25%
Pilatz	50%						

<sup>a</sup> 60% acquired phimosis/30% congenital.

<sup>b</sup> Only patients under the age of 5 years.

<sup>c</sup> Clinical diagnosis.

report by Vincent et al., hydrocortisone or triamcinolone were used as treatment [16], whereas the report by Kiss et al. used pre-operative mometasone 0.05% [15]. Both reported a better outcome regarding retractability of the foreskin and poor results regarding the degree of inflammatory involvement of the foreskin in biopsies compared with placebo.

Wilkinson reported foreskin-preserving techniques, with preputioplasty and injection of intra-lesional triamcinolone intraoperatively, with a success rate of 81% [17]. Vincent reported good outcomes with this technique as a second line, after failed hydrocortisone topical treatment, with low rates of secondary circumcision (15/56 patients) [16,17].

Regarding the use of immunosuppression in BXO, Ebert et al. demonstrated that treatment with tacrolimus 0.1% after surgery (complete circumcision), resulted in recurrence in 9%, which was successfully treated with a new cycle of the drug [12]. They found that tacrolimus 0.1% ointment is a safe and well-tolerated adjuvant option after surgery for BXO, particularly if there is a risk of complicated outcome caused by meatal or glandular involvement, which can be estimated, in certain cases, at the time of surgery.

Meatoplasty is the most common urinary reconstructive surgery associated with BXO, even though not frequently needed, it is described in up to 36% of patients from pediatric urology centers.

### The authors' experience

A combined series between our institutions, Exequiel Gonzales Cortes Hospital (Santiago, Chile), St Georges Hospital (London, UK) and Children's University Hospital (Dublin, Ireland) was evaluated.

This series, a retrospective study over a 10-year period (2002–2012), reviewed 146 cases of BXO confirmed by histopathology. The authors acknowledged that this study could have some bias, as suspicion of BXO was the only reason for pathological study. This issue could represent a falsely high incidence of this pathology in our hospitals.

The mean age at the time of surgery was 8 years old (23 days–18 years), with median 10 years old.

Only one patient had an associated pathology, having had multiple reconstructive surgeries for hypospadias repair.

The surgical treatment was circumcision in 100% of the primary cases. A redo urethroplasty was done in the patient with multiple previous repairs. Topical corticosteroids were used in a random way, therefore data analysis was not possible.

Follow-up data were obtained for 111/143 patients (76%) with median follow-up of 50 days. Complications were divided into early and late, with an overall complication rate of 21% ( $n = 24$ ) in the 111 patients. Early complications (within 30 post-operative days) were detected in 11/111 boys. Wound infections were seen in four patients (3%); all four were treated with a course of oral antibiotics for 5–7 days. Six patients (5%) had post-operative bleeding, all of whom were treated non-operatively. One patient had urinary retention, requiring a transitory urinary catheter which was removed without complications.

Late complications – 30 days post operatively – were noted in 13/111 patients (11%). Eight of those showed symptomatic meatal stenosis; all required dilatations and/or meatotomy or meatoplasty. In five of the 13 patients, restenosis was reported requiring a redo-circumcision. It is worth mentioning that all these five cases have residual foreskin; two of the five had received topical corticoids at the time of initial surgery.

### Discussion

BXO is described as an infrequent disease during childhood. However, in recent years its incidence appears to be increasing [5–7,9,10].

This can be interpreted from various perspectives: (1) an increased incidence as more foreskin samples have been sent for histopathological examination, and/or (2) surgeons are more aware about this disease, therefore, they are examining the foreskin more carefully, being more suspicious. Unfortunately, we cannot estimate the real incidence because only in one center were all excised foreskins routinely sent for histology.

In our series, circumcision was the definitive treatment in 96% of the patients, similar to other significant series [5–7,9,10]. However, it is noted that in Chilean data some patients without clinical suspicion of BXO and for cultural reasons were subjected to partial circumcision. As they

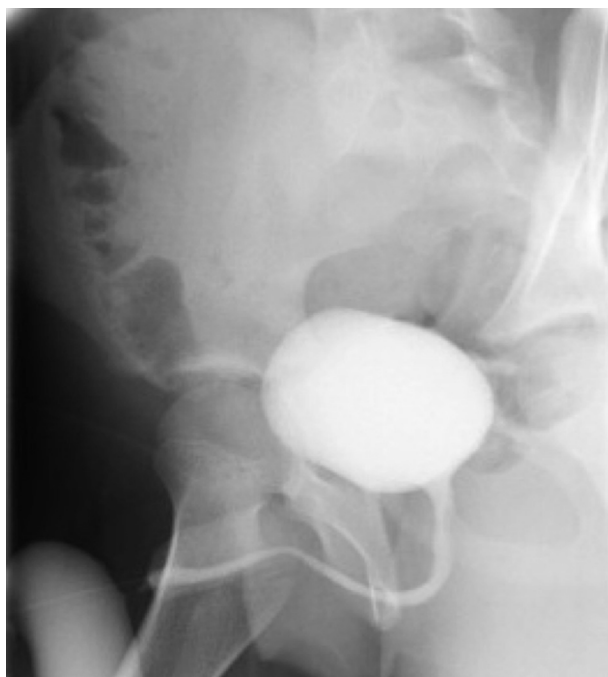
developed a restenosis, all five underwent a second circumcision, allowing a pathology diagnosis for BXO.

The only studies looking for other kinds of treatments were reports by Vincent and Wilkinson, in which they performed foreskin conservative surgeries associated with intralesional or topic corticoids as first-line treatment, both with at least 12 months of follow-up [16,17].

An option for those who would prefer to retain the foreskin in the face of BXO is the use of topical steroids. However, it appears that only those mild cases of BXO limited to the prepuce respond to topical steroids. The difficulty is recognizing the 'mild' cases. However, if good response is not achieved, surgery is advised either a preputioplasty with intralesional triamcinolone or total circumcision [15–17]. However, the lack of a histological diagnosis means that a true comparison is difficult as 'mild' BXO could be something other than BXO.

The most feared complications of BXO are meatal stenosis and urethral stricture. Reported incidence is 4%–47% of meatal stenosis [1,2] and 20%–60% of urethral strictures [1,2,8]. These issues had been related to penile carcinoma; however, there is no such evidence within the pediatric population [12].

Meatal and urethral involvement (Fig. 3) in BXO may cause serious clinical problems, as urinary obstruction, which may arise from obstructive symptoms and can lead to renal failure [23]. Additional treatment, such as urethral dilatation or surgical intervention (meatoplasty, urethroplasty), is often necessary [6,14]. When BXO is demonstrated after circumcision, we would recommend preventive treatment with topical corticosteroids and a long-term follow-up, looking for early diagnosis in case of recurrent BXO and/or obstructive micturition.



**Figure 3** Voiding cystogram showing meatal stenosis and urethral involvement in BXO.

There are no reports of cases of penile squamous cell carcinoma (SCC) in children with BXO as there are no series with long-term follow-up on this issue. However, in adults a relationship has been shown between BXO and SCC with a histologic confirmation of BXO and synchronously SCC in 2.2%–28% [1,24,25]. As no long-term follow-up has been described in children with BXO, and it may have some relation with SCC, we recommend a long follow-up in this cases by a urology team; pediatric urologist followed by adult urologist.

In conclusion, BXO is a condition that is present in the pediatric population, more often than previously reported. Thus the recommendation is to be more suspicious making a better and earlier diagnosis, trying to avoid further complications. Recommended treatment is circumcision, ideally with adjuvant therapy such topical steroids. In a few particular cases, preserving foreskin surgery may be an option with the addition of intralesional steroids (triamcinolone). In this review the general outcomes for BXO were good, nevertheless closer and longer follow-up is needed.

### Conflict of interest

None.

### Funding

None.

### References

- [1] Depasquale I, Park AJ, Bracka A. The treatment of balanitis xerotica obliterans. *BJU Int* 2000;86:459–65.
- [2] Pugliese J, Morey A, Peterson A. Lichen sclerosus: review of the literature and current recommendations for management. *J Urol* 2007;178:2268–76.
- [3] Catterall RD, Oates JK. Treatment of balanitis xerotica obliterans with hydrocortisone injections. *Br J Vener Dis* 1962;38:75–7.
- [4] Bale PM, Lochhead A, Martin HC, Gollow I. Balanitis xerotica obliterans in children. *Pediatr Pathol* 1987;7:617.
- [5] Jayakumar S, Antao B, Bevington O, Furness P, Ninan GK. Balanitis xerotica obliterans in children and its incidence under the age of 5 years. *J Ped Urol* 2012;8:272–5.
- [6] Kiss A, Király L, Kutasy B, Merksz M. High incidence of balanitis xerotica obliterans in boys with phimosis: prospective 10-year study. *Pediatr Dermatol* 2005;22:305–8.
- [7] Bochove-Overgaauw D, Gelders W, De Vylder A. Routine biopsies in pediatric circumcision: (non) sense? *J Ped Urol* 2009; 5:178–80.
- [8] Kizer WS, Prarie T, Morey AF. Balanitis xerotica obliterans: epidemiologic distribution in an equal access health care system. *South Med J* 2003;96:9–11.
- [9] Pilatz A, Altinkilic B, Schormann E, Maegel L, Izykowski N, Becker J, et al. Congenital phimosis in patients with and without lichen sclerosus: distinct expression patterns of tissue remodeling associated genes. *J Urol* 2013;189:268–74.
- [10] Mattioli G, Repetto P, Carlini C, Granata C, Gambini C, Jasonni V. Lichen sclerosus et atrophicus in children with phimosis and hypospadias. *Pediatr Surg Int* 2002;18:273–5.
- [11] Yardley IE, Cosgrove C, Lambert AW. Paediatric preputial pathology: are we circumcising enough? *Ann R Coll Surg Engl* 2007;89:62–5.

- [12] Ebert AK, Rösch WH, Vogt T. Safety and tolerability of adjuvant topical tacrolimus treatment in boys with lichen sclerosus: a prospective phase 2 study. *Eur Urol* 2008;54: 932–7.
- [13] Becker K. Lichen sclerosus in boys. *Dtsch Arztebl Int* 2011;108: 53–8.
- [14] Gargollo P, Kozakewich H, Bauer S, Borer J, Peters C, Retik A, et al. Balanitis xerotica obliterans in boys. *J Urol* 2005;174: 1409–12.
- [15] Kiss A, Csontai A, Pirot L, Nyirady P, Merksz M, Kiraly L. The response of balanitis xerotica obliterans to local, steroid application compared with placebo in children. *J Urol* 2001; 165:219–20.
- [16] Vincent M, MacKinnon E. The response of clinical balanitis xerotica obliterans to the application of topical steroid-based creams. *J Pediatr Surg* 2005;40:709–12.
- [17] Wilkinson D, Lansdale N, Everitt L, Marven S, Walker J, Shawis R, et al. Foreskin preputioplasty and intralesional triamcinolone: a valid alternative to circumcision for balanitis xerotica obliterans. *J Pediatr Surg* 2012;47:756–9.
- [18] Mohammed A, Shegil IS, Christou D, Khan A, Barua JM. Paediatric balanitis xerotica obliterans: an 8-year experience. *Arch Ital Urol Androl* 2012;84:12–6.
- [19] Powell J, Wojnarowska F. Lichen sclerosus. *Lancet* 1999;353: 1777–89.
- [20] Dillon WI, Saeed GM, Fivenson DP. *Borrelia burgdorferi* DNA is undetectable by polymerase chain reaction in skin lesions of morphea, scleroderma or lichen sclerosus et atrophicus in patients of North America. *J Am Acad Dermatol* 1995;33: 617–20.
- [21] Terlouw A, Santegoets LA, van der Meijden WI, Heijmans-Antonissen C, Swagemakers SM, van der Spek PJ, et al. An autoimmune phenotype in vulvar lichen sclerosus and lichen planus: a Th1 response and high levels of microRNA-155. *J Invest Dermatol* 2012;132(3 Pt 1):658–66.
- [22] Edmonds E, Barton G, Buisson S, Francis N, Gotch F, Game L, et al. Gene expression profiling in male genital lichen sclerosus. *Int J Exp Pathol* 2011;92:320–5.
- [23] Christman M, Chen J, Holmes N. Obstructive complications of lichen sclerosus. *J Pediatr Urol* 2009;5:165–9.
- [24] Nasca MR, Innocenzi D, Micali G. Penile cancer among patients with genital lichen sclerosus. *J Am Acad Dermatol* 1999;41: 911–4.
- [25] Pietrzak P, Hadway P, Corbishley C, Watkin N. Is the association between balanitis xerotica obliterans and penile carcinoma underestimated? *BJU Int* 2006;98:74–6.